Berlin

Common Problems in Hematology
for Long Case Examination

Chakri Naruebodindra Medical Institute
Faculty of Medicine Ramathibodi Hospital, Mahidol University
November 27, 2022

Outlines

I. Overview on long case examination
II. How to approach the patient with hematologic condition
III. Practices for long case scenario
- Case 1: 50 y/o male presented with progressive tiredness for 3 mo.
- Case 2: 26 y/o female presented with persistent dry cough for 2 mo.
- Case 3: 65 y/o male presented with shortness of breath for 3 days.

I. Overview on 'long case examination'

- ✓ **Patient profile**
- ✓ **Clinical:**
  Pertinent findings from **history** and **physical examination**
- ✓ **Relevant labs:**
  CBC with peripheral blood smear
  Hb globin typing
  Coagulogram (PT, PTT, TT)
  Fibrinogen / D-dimer / ELT
  Chemistry; including LDH
  SPEP / M. protein / IFE / IgA IgG IgM level, serum free light chain
  UPEP / urine bence jones protein
  Thrombophilic tests (protein C, protein S, antithrombin, antiphospholipid panels)
- ✓ **Radiology:**
  Interpret X-ray, ultrasound, doppler ultrasound, CT, MRI brain
- ✓ **Pathology:**
  BMA
  BM Bx or LN Bx (+ basic IHC)

Structure of long case in hematology

How to approach (Hypothesis refinement)

- **Hypothetico-deductive method** → Differential diagnoses
- **Pattern recognition**

Diagnosis

- **1. Disease with hematologic presentation**
- **2. Hematologic disorder with systemic manifestation**
- **3. Hematology lab interpretation**

Scaling: **Frequency** | **Difficulty** | **Variety**

- **Natural history** (Epidemiology / pathogenesis)
- **Assessment** (Staging / Scale / Score)
- **Treatment**
- **Prognosis**
- **Patient education**

Symptomatology for hematologic problems in long case examination

Dyspnea
Syncope
Chest pain
Dizziness

CBC
Blood smear

Anemia

Cytopenia
Anemia
Bicytopenia
Pancytopenia

Petechiae
Purpura
Ecchymosis
Melena / hematochezia
Vaginal bleeding
Hemarthrosis
Hematomas

CBC
Blood smear
Coagulogram

Bleeding tendency

Cytopenia
Thrombocytopenia
Bicytopenia
Pancytopenia
Platelet dysfunction
Coagulopathy

Abdominal distension

CBC
Blood smear
U/S, CT abdomen

Splenomegaly

Chronic myeloid leukemia (CML)
Primary myelofibrosis (PMF)

Stroke manifestations
Weakness / impaired sensory
Visual disturbance
Ataxia
Memory defect
ACS manifestations
Chest pain
Arrhythmia
Syncope
PAD manifestations
Unilateral leg pain
Venous thrombosis manifestations
Unilateral leg swelling: DVT
Unilateral arm swelling: UEDVT
Dyspnea: PE
Abdominal pain:
splanchnic vein thrombosis
Ascites / jaundice: Budd-Chiari
Headache: CSVT

CBC
Imaging for thrombosis

Thrombosis

Polycythemia vera (PV)
Essential thrombocythemia (ET)
Leukostasis syndrome in leukemia
Cancer associated thrombosis (CAT)
Antiphospholipid syndrome (APS)
Hereditary thrombophilia

Enlarged lymph node

CBC, ESR
Blood smear
LDH
CT neck, chest, abdomen
(or MRI / PET-CT)

Lymphadenopathy

Prolonged fever
Weight loss
Rheumatisms
Skin rash
Ascites / Effusion
Abnormal mass

Lymphoma

Neurologic manifestations
Impaired sensory
Visual disturbance
Ataxia
Proteinuria

CBC
Blood smear
SPEP or Immunofixation
Ig level
Serum FLC

Paraproteinemia

Bone pain
Renal failure
Hypercalcemia

Multiple myeloma (MM)
MGUS
Primary AL amyloidosis
POEMS
Waldenstrom macroglobulinemia

Physical examination of the patient with hematologic condition

Thalassemia

Thalassemic facies
Bone changes
Height

Hematologic malignancies

Pallor
Jaundice

Pallor (+/- Jaundice)

Cervical
Supraclavicular
Lymphanopathy

Signs of congestive heart failure
Engorged JVP
S3 gallop
Loud P2

Hepatomegaly

Axillary
Epitrochlear

Splenomegaly

Splenomegaly

Genital organ (M)
Breast (F)
Pubic hair

Inguinal
Femoral

Skin rash

How to approach anemia

Anemia
Hb <13 g/dL (M) or <12 g/dL (F)

Bleeding likely?

Yes → Consider EGD, colonoscopy, imaging, etc.

No → Obtain smear and reticulocyte count

Reticulocyte index <2% → BM production failure (Hypoproliferation)

Nutrient deficiency
Iron deficiency anemia
Folate deficiency
Vitamin B12 deficiency
Copper deficiency
Zinc excess

↓ EPO activity
Chronic kidney disease
Anemia of inflammation

↓ Space in marrow
Hematologic malignancies
Metastatic solid cancers
Myelofibrosis
Neuroblastoma
Osteopetrosis
Sarcoidosis
Storage cell disorders

Defect of stem cell
Aplastic anemia
Myelodysplastic syndrome
Inherited BM failure
Pure red cell aplasia

Reticulocyte index ≥2% → Destruction or blood loss (Adequate reticulocyte response) → **Bleeding**; consider internal bleeding (e.g., pleural, intraabdominal, retroperitoneal, thigh) → Consider EGD, colonoscopy, imaging, etc.

Destruction or blood loss (Adequate reticulocyte response) → Work up for hemolysis

Hemolysis confirmed → Direct Coombs' test

Direct Coombs' test **+** → **Antibody mediated hemolysis**
Autoimmune
Warm type AIHA
Cold type AIHA
Alloimmune
Hemolytic transfusion reactions

Direct Coombs' test **-** → **Non-antibody mediated hemolysis**
Extrinsic
Hypersplenism
Infections (malaria, babesiosis)
MAHA
Intrinsic
Membrane defects (hereditary spherocytosis, SEA ovalocytosis, Paroxysmal nocturnal hemoglobinuria)
Enzymatic deficiencies (G6PD, pyruvate kinase)
Hemoglobinopathies (Thalassemia, Sickle cell anemia)

How to approach hemolytic anemia

Suspected hemolytic anemia
(reticulocytosis, ↑ LDH)

Blood smear
Bilirubin
Haptoglobin
Urine hemoglobin
Urine hemosiderin
Urine urobilinogen

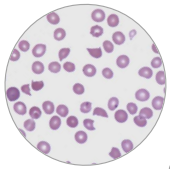

Schistocytes
Bilirubin normal to ↑
Haptoglobin ↓ or absent
Urine hemoglobin present
Urine hemosiderin present
Urine urobilinogen absent

Intravascular hemolysis

Microangiopathic: DIC, TTP, HUS
Obstetric complications: HELLP, abruptio placenta
Mechanical heart valve
Snake venom
Infections: malaria, babesia, clostridium
G6PD deficiency
Thalassemia - hemolytic crisis
Hemolytic transfusion reaction: ABO incompatibility
PNH
Paroxysmal cold hemoglobinuria

Splenomegaly

Spherocytes, spur cells, bite cells, etc.
Bilirubin ↑ (especially indirect)
Haptoglobin normal to ↓
Urine hemoglobin absent
Urine hemosiderin absent
Urine urobilinogen ↑

Extravascular hemolysis

Hemoglobinopathies: Thalassemia, Sickle cell
Membrane defects: HS, HE, SAO
Hypersplenism
IVIG infusion
AIHA
Delayed hemolytic transfusion reaction

How to approach pancytopenia

Pancytopenia
Hb <13 g/dL (M) or <12 g/dL (F) +
WBC <4000/mm³ +
Plt <150000/mm³

Bone marrow failure

Aplasia
Aplastic anemia
Autoimmune cytopenia
Cytotoxic drug / Toxin /Radiation
Viral infection (HIV, EBV, CMV, Parvovirus)
TB / NTM/ Fungal infection
Hemophagocytosis

Dysplasia
PNH
MDS
Vitamin B12 deficiency
Folate deficiency
Copper deficiency

Infiltration
Hematologic malignancies
Metastatic solid cancers
Myelofibrosis
Neuroblastoma
Osteopetrosis
Sarcoidosis
Storage cell disorders

Peripheral destruction
SLE
Combined immune cytopenia
Overwhelming infection / Severe DIC

Sequestration
Hypersplenism

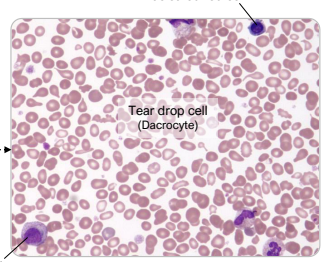

Leukoerythroblastic (Myelophthisis) blood picture

How to approach splenomegaly

Splenomegaly

Congestive
Evidences of portal hypertension or coagulopathy

Cirrhosis
Hepatic vein thrombosis
Portal vein thrombosis
Splenic vein thrombosis

Non-portal related

Infectious
Bacterial
Parasite
Viral
Fungal

Inflammatory
SLE
Sarcoidosis
Serum sickness

Infiltrative
Malignant
Lymphoma
Leukemia
MPNs (CML, PV, ET, PMF)
Non-malignant
Gaucher's disease
Glycogen storage disease
Amyloidosis

Hemolytic disease
(Extravascular hemolysis)

Differential diagnoses of massive splenomegaly

Myeloproliferative neoplasms
- Chronic myeloid leukemia (CML)
- Chronic myelomonocytic leukemia (CMML) and MDS/MPN
- Primary myelofibrosis (PMF)

Lymphoproliferative disorders
- Non-Hodgkin lymphoma
  - Splenic marginal zone lymphoma (SMZL)
  - Mantle cell lymphoma (MCL)
  - Follicular lymphoma (FL)
  - Diffuse large B cell lymphoma (DLBCL)
  - T cell large granular lymphocyte leukemia (T-LGL)
  - Hepatosplenic lymphoma
- Chronic lymphocytic leukemia (CLL)
- Hairy cell leukemia

Infections
- Chronic malaria (Hyperreactive malarial syndrome)
- Visceral leishmaniosis
- Mycobacterium avium complex

Chronic hemolytic anemia
- Thalassemia major

Infiltrative diseases
- Glycogen storage disease (e.g. Gaucher disease)
- Lysosomal storage diseases

Clot formation

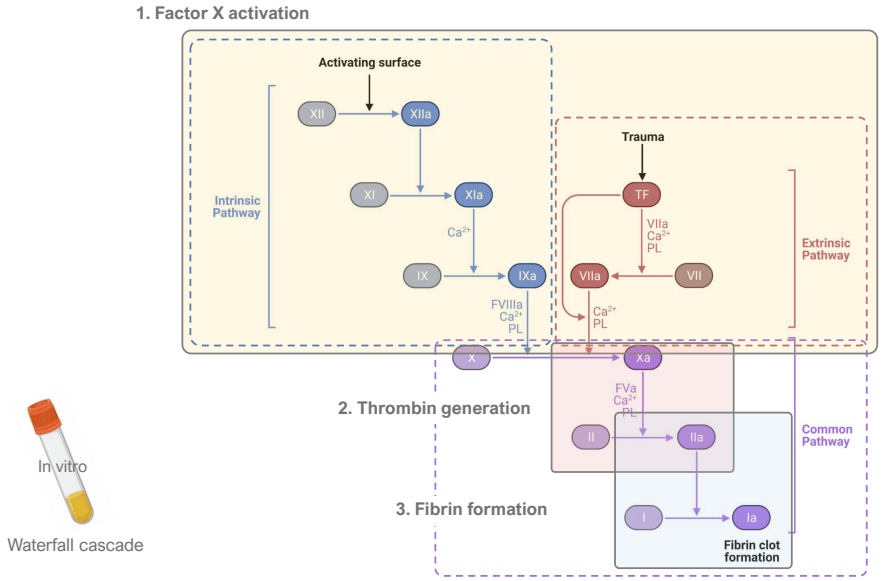

In vitro

Waterfall cascade

How to approach bleeding tendency

Clinical approach

Features	Primary hemostasis	Secondary hemostasis
Onset of bleeding after trauma	Spontaneous / immediately trauma	Delayed after
Sites of bleeding • Skin • Mucous membrane • Other sites	**Superficial surfaces** Petechiae, ecchymoses Nasal, oral, GI, GU Rare	**Deep tissues** Hematomas Rare Joint, muscle, retroperitoneal
Bleeding responding to pressure	Yes	No

- Vascular defect
- Platelet defect
  - Thrombocytopenia → p14 Approach to thrombocytopenia
  - Platelet dysfunction
- Coagulopathy → p15 Approach to coagulopathy 1; p16 Approach to coagulopathy 2; p17 Approach to coagulopathy 3

How to approach thrombocytopenia

Thrombocytopenia

*Exclude **pseudothrombocytopenia***
- Platelet clumping
- Platelet satellitism

- **Underproduction**
  - Aplastic anemia / Amegakaryocytic thrombocytopenia
  - Acute leukemia
  - Infection
  - Drug induced / Ethanol induced
  - Myelopthisis
  - Megaloblastic anemia
- **Peripheral destruction**
  - **Immune**
    - **Primary immune thrombocytopenia (ITP)**
    - **Secondary ITP** (SLE, HIV, HCV, H. pylori, Lymphoma, CLL, Drug, Graves's disease)
  - **Non-immune** (MAHA)
    - TTP, HUS
    - **DIC**
- **Dilutional thrombocytopenia / Sequestration**

How to approach coagulopathy 1

Prolonged aPTT, normal PT

- Bleeding
  - Mixing test correctable?
    - Correctable
      - **Hemophilia A, B**, C (Factor VIII, IX, XI deficiency)
      - **Von Willebrand disease**
    - Uncorrectable
      - **Factor VIII inhibitor**
      - Inhibitors of factor IX, XI
- No bleeding
  - Mixing test correctable?
    - Correctable
      - Factor XII deficiency
      - Deficiency of HMWK, PK
    - Uncorrectable
      - Lupus anticoagulant
      - Inhibitors of factor XII, HMWK, PK

How to approach coagulopathy 2

Prolonged PT, normal aPTT

*Exclude **heparin effect or intoxication***

- Congenital
  - Factor VII deficiency
- Acquired
  - Mixing test correctable?
    - Correctable
      - **Liver disease**
      - **Warfarin**
      - **Vitamin K deficiency**
      - Hypofibrinogenemia
      - **DIC**
    - Uncorrectable
      - Factor VII inhibitor

How to approach coagulopathy 3

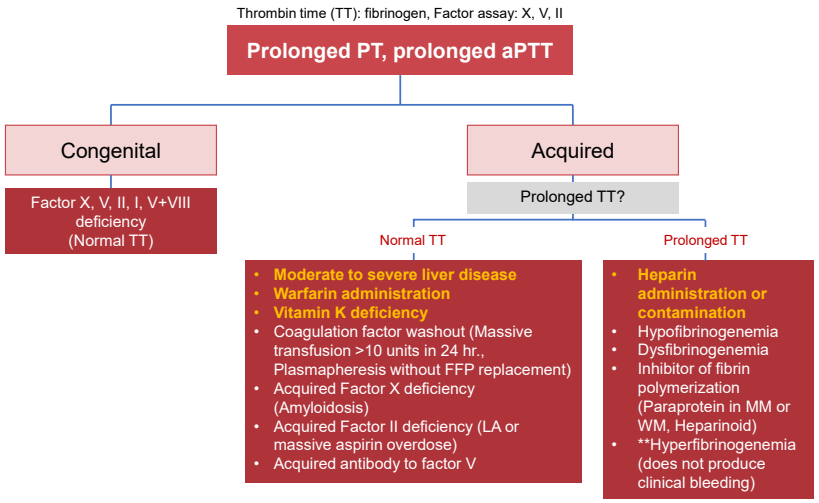

Causes of abnormal bleeding not detected by TT, PT, PTT, bleeding time, and platelet count

Poor fibrin polymer cross-linking
- Factor XIII deficiency / inhibitor of Factor XIII
- Abnormal fibrinogen

Abnormal or excessive fibrinolysis
- a_2-antiplasmin deficiency
- Increased TPA, TPA inhibitor deficiency
- Urokinase
- Primary fibrinolysis

Mild bleeding disorders
- Platelet dysfunction
- von Willebrand disease

Vascular purpura
- Scurvy
- Amyloid
- Senile purpura
- Vasculitis
- Henoch-Schoenlein purpura
- Congenital connective tissue disorders (Marfan's syndrome, Ehlers-Danlos syndrome)
- Cryoglobulins
- Autoerythrocyte purpura
- Hereditary hemorrhagic telangiectasia

III. Practices for 'long case scenario'

Examples from previous long case examinations

1. **Disease with hematologic presentation**
   - Case A: **Acute anemia** in a young female — **SLE with AIHA**
   - Case B: **Pancytopenia** in a young male with AIDS — **Disseminated cryptococcosis**
2. **Hematologic disorder with systemic manifestation**
   - Case C: A middle-aged male with acute hemiparesis — **PV with acute stroke**
   - Case D: An elderly male with new-onset ascites — **AITL** (Angioimmunoblastic T cell lymphoma)
3. **Hematology lab interpretation**
   - Case E: A young female with abdominal pain **Eosinophilia** — ***Fasciola hepatica* liver abscess**
   - Case F: An elderly male with acute fever **Neutrophilia** — **Leukemoid reaction**

etc.

Case 1

50 y. male, lawyer

Clinical:
Progressive tiredness for 3 mo.
Significant weight loss
Low back pain
Pallor

Labs:
CBC: WBC 4×10⁹/L (N 45, L 45, M 5),
Hb 9.5, Plt 120×10⁹/L, NRC 1/100
Reticulocyte index (RI) 1%
Cr 1.4, Ca^{2+} 11.5, ALP 50, Alb 2.5, Glo 6.0

Radiology:

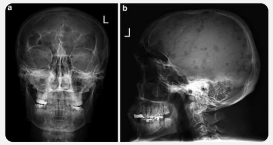

Film skull AP and lateral show multiple punch-out lesions.

CXR shows osteolytic lesions at left clavicle.

MRI spine demonstrates L3 compressed fracture and diffuse osteopenia with multiple osteolytic lesions.

Case 1

How to approach

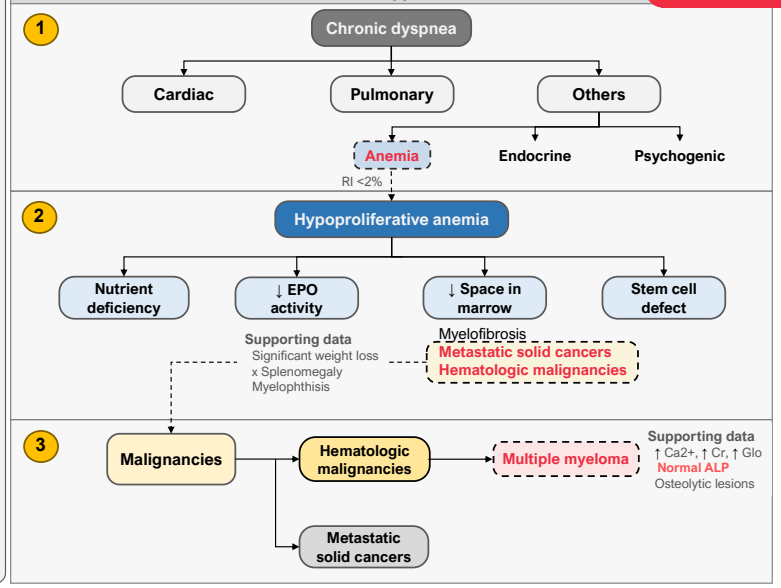

50 y. male, lawyer

Clinical:
Progressive tiredness for 3 mo.
Significant weight loss
Low back pain
Pallor

Labs:
CBC: WBC 4×10⁹/L (N 45, L 45, M 5),
Hb 9.5, Plt 120×10⁹/L, NRC 1/100
Reticulocyte index (RI) 1%
Cr 1.4, Ca^{2+} 11.5, ALP 50, Alb 2.5, Glo 6.0

Radiology:

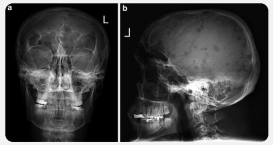

Film skull AP and lateral show multiple punch-out lesions.

CXR shows osteolytic lesions at left clavicle.

MRI spine demonstrates L3 compressed fracture and diffuse osteopenia with multiple osteolytic lesions.

Case 1

Multiple myeloma

Frequency +++ **Difficulty ++** **Variety +++**

Diagnosis

Suspected MM

Screening with SPEP +/- FLC

Criteria
1. Clonal marrow plasma cells ≥10% or extramedullary plasmacytoma
2. Any 1 or more of myeloma defining events
   2.1 End-organ damage
   - Ca >11 mg/dL
   - Cr >2 mg/dL (or CrCl <40)
   - Hb <10 g/dL
   - Osteolytic lesion(s) from imaging
   2.2 Biomarkers of malignancy
   - *Clonal marrow plasma cells ≥60%
   - Involved:uninvolved SFC ≥100
   - >1 focal lesions on MRI

*Clonality shows light chain restriction

Serum IFE, M protein, Ig and FLC, Bone marrow study (CD138, κ, λ)

Confirmed MM

Transplant ineligible patient
Age >75
Frail
Comorbidities

Transplant eligible?
Yes →
No →

Staging

Revised ISS
I = β2m <3.5 mg/L + Alb >3.5 + standard risk clonal cytogenetics abnormalities (CA) by FISH + normal LDH (mPFS 66 mo.)
II = Nor R-ISS stage I or III (mPFS 42 mo.)
III = β2m >5.5 mg/dL or *High risk CA or high LDH (mPFS 29 mo.)

High risk CA
t(4;14)
t(14;16)
del(17p)

Treatment

Transplant candidate

Induction regimen with using combination therapy with **PI base**
(*Avoid lenalidomide / melphalan)

Autologous SCT

Consolidation or Maintenance therapy

Non-transplant candidate

Combination therapy with PI (e.g., bortezomib) or Imids (e.g., lenalidomide) +/- traditional agents (cyclophosphamide, melphalan, etc.)

Renal complications in multiple myeloma

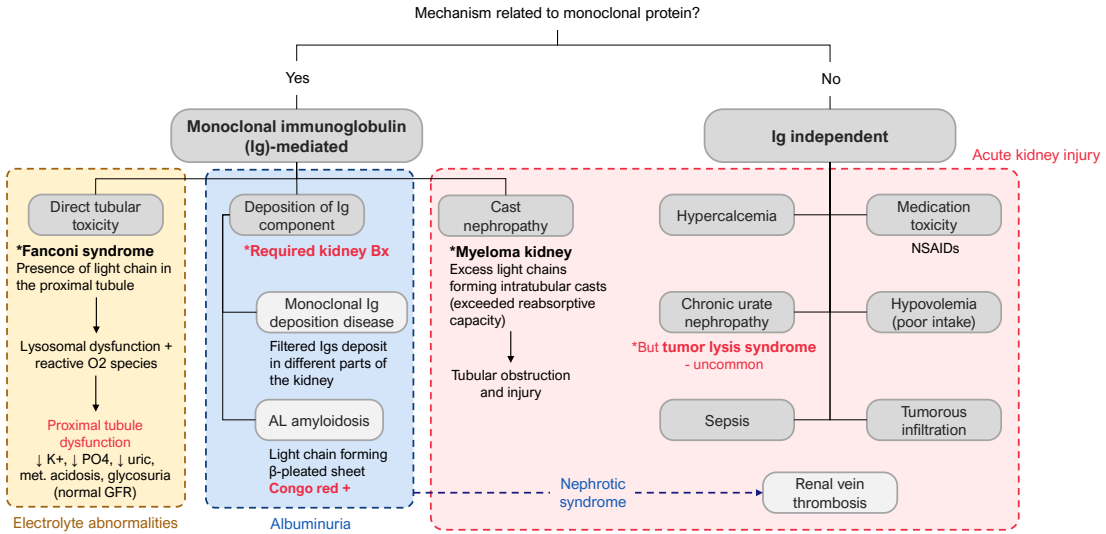

Case 2

26 y. female, kindergarten-teacher

Clinical:
Persistent dry cough and progressive positional related SOB for 2 mo.
Alcohol intolerance
Significant weight loss
Enlarged left cervical LN

Lab:
CBC: WBC 10x10^9/L (N 60, L 30, E 5), Hb 11, Plt 550x10^9/L
ESR 60, LDH 280, Cr 0.8, LFT WNL

Radiology:

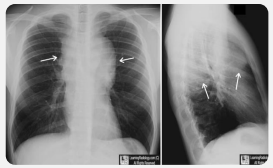

PA and right lateral CXR show large, bulky, lobulated soft tissue mass in mediastinum.

CT chest demonstrates an ill-defined and homogeneous 9x11 cm. mass in the right anterior extending to middle mediastinum.

Case 2

How to approach

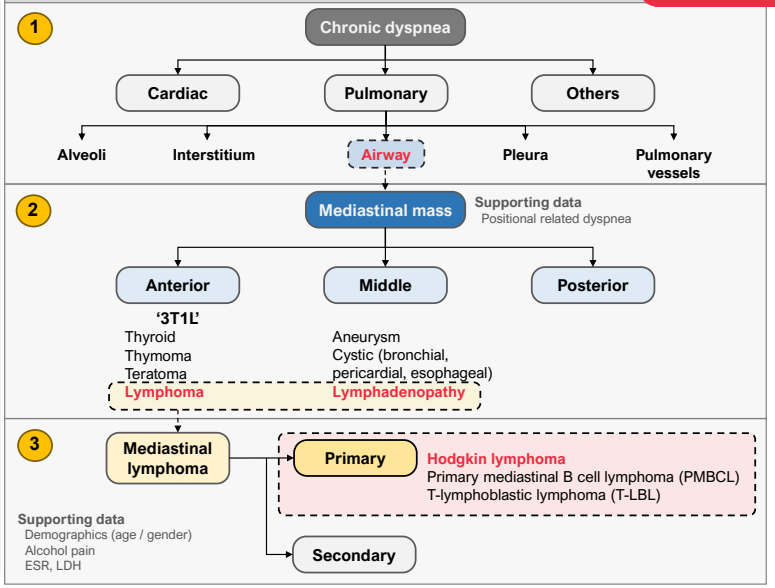

26 y. female, kindergarten-teacher

Clinical:
Persistent dry cough and progressive positional related SOB for 2 mo.
Alcohol intolerance
Significant weight loss
Enlarged left cervical LN

Lab:
CBC: WBC 10x10^9/L (N 60, L 30, E 5), Hb 11, Plt 550x10^9/L
ESR 60, LDH 280, Cr 0.8, LFT WNL

Radiology:

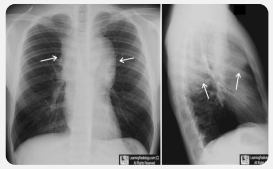

PA and right lateral CXR show large, bulky, lobulated soft tissue mass in mediastinum.

CT chest demonstrates an ill-defined and homogeneous 9x11 cm. mass in the right anterior extending to middle mediastinum.

Case 2

Hodgkin lymphoma

Frequency ++ **Difficulty ++** **Variety ++**

Natural history

Incidence
3/100K
Bimodal age
M > F

Clinical features
Asymptomatic ↑ LN
Anterior mediastinal mass

Subtypes of cHL
Nodular sclerosis
Mixed cellularity
Lymphocyte-depleted
Lymphocyte-rich

Histology

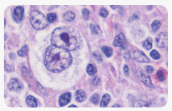

Reed-Sternberg cell
(CD20 -, CD30 +)

Assessment

Ann Arbor staging

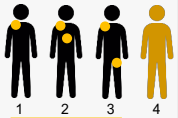

(E = Extranodal)

Stage
Limited: I, II non bulky
Advanced: II bulky, III, IV

Treatment

1L Chemotherapy with ISRT
Limited-stage:
ABVD x 2-4 (interim PET-CT) then ISRT
Advanced stage:
ABVD x 6 then locally RT for PET-positive residual disease

r/r disease:
Anti-CD30 + chemo
Novel agents

Prognosis

Determined by stage
Stage I, II: 90% cure
Stage III, IV: 30% cure

Hodgkin vs Non-Hodgkin lymphoma

	HODGKIN LYMPHOMA		NON-HODGKIN LYMPHOMA
Age	Young adults		More common ages 40-70 yr
B symptoms	40%		20%
Spread	Generally contiguous nodal groups		Multiple remote nodal groups often involved
Stage at presentation	>80% early stage I and II		>85% late stage III and IV
Nodal groups	Thoracic	65-85%	25-40%
	Para-aortic	25-35%	45-55%
	Mesenteric	5%	50-60%
Extranodal disease	CNS	<1%	2%
	GI tract	<1%	5-15%
	Genitourinary tract	<1%	1-5%
	Bone marrow	5%	20-40%
	Lung parenchyma	8-12%	3-6%
	Bone	<1%	1-2%

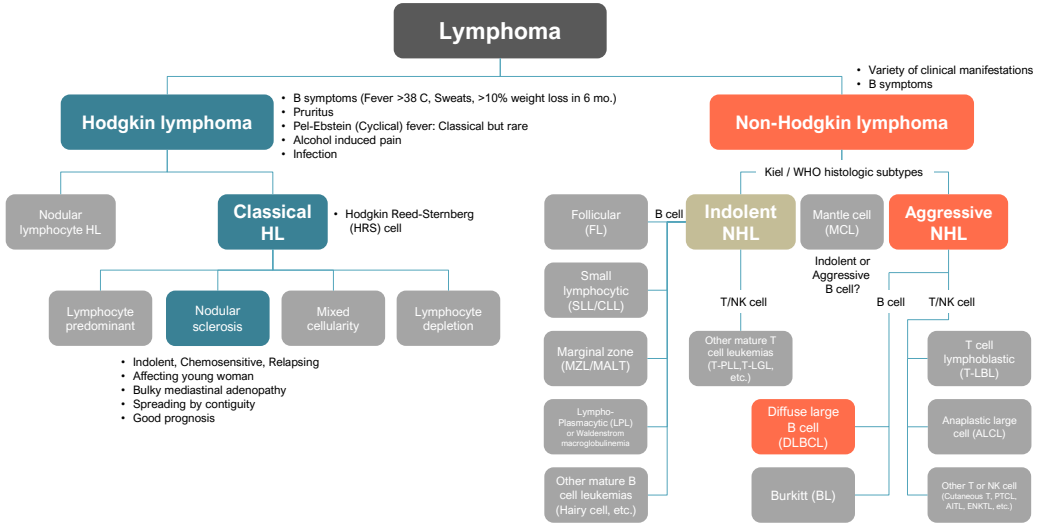

Differential diagnosis: lymphoma in different setting

Young adult	Anterior mediastinal mass	HIV related	Primary BM (+/- splenomegaly)	HLH associated	HyperIg
Hodgkin	Hodgkin (F,Y)	PCNSL	LPL or WM	DLBCL or IVL	LPL or WM (IgM)
DLBCL	PMBCL (F,35)	Burkitt	MZL	ALCL	MZL (IgG)
Burkitt	ALCL (M/F, Y)	DLBCL (Imm.)	MCL	SPTCL	AITL (Polyclonal)
ALCL	T-LBL (M,Y)	PBL	SMZL	T-LBL	
T-LBL	DLBCL (M/F, E)	PEL	HCL	1º cut. Γδ-T-cell	
		Hodgkin (MC/LD)	T-LGL	Hodgkin (MC/LD)	

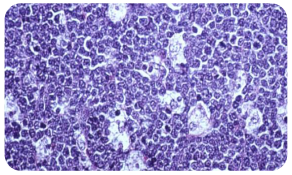

Burkitt lymphoma
Starry sky pattern

Mycosis fungoides
(cutaneous T cell lymphoma)

ALCL = Anaplastic large cell lymphoma, T-LBL = T cell lymphoblastic lymphoma, PMBCL= Primary mediastinal B cell lymphoma, T-LGL = Large granular lymphocyte leukemia
SPTCL = Subcutaneous panniculitis like T cell lymphoma, 1o cut. Γδ-T-cell = Primary cutaneous gamma-delta T cell lymphoma, SMZL = Splenic marginal zone lymphoma, MCL = Mantle cell lymphoma
PBL = Plasmablastic lymphoma, PEL = Primary effusion lymphoma, LPL = lymphoplasmacytic lymphoma, AITL = Angioimmunoblastic T cell lymphoma, HCL = Hairy cell leukemia, IVL = Intravascular lymphoma

65 y. male, farmer

Clinical:
Acute dyspnea on exertion for 3 days.
Chest pain
SpO_2 92%, HR 110/min

Lab:
EKG: S1Q3T3 pattern
ABG: PaO_2 60, CO_2 18, respiratory alkalosis
Troponin -ve
CBC: WBC 10x10⁹/L (N 55, L 30, M 8, E 5),
Hb 12.5, Plt 780x10⁹/L
Coag WNL, , Cr 0.8

Radiology:

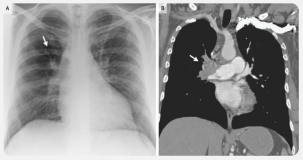

Echo. shows D shaped LV in diastole
CXR shows **Westermark sign** in the right lung.
CTPA demonstrates filling defects within the right pulmonary trunk.

Case 3

How to approach

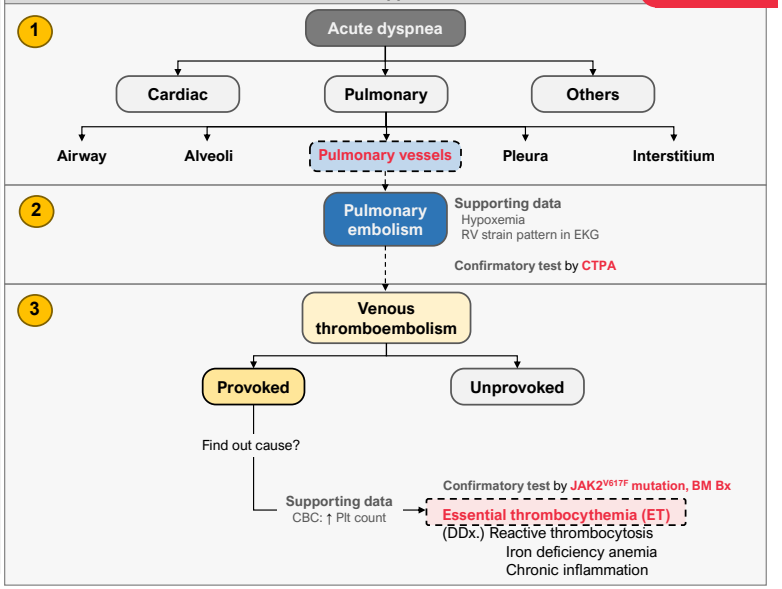

65 y. male, farmer

Clinical:
Acute dyspnea on exertion for 3 days.
Chest pain
SpO_2 92%, HR 110/min

Lab:
EKG: S1Q3T3 pattern
ABG: PaO_2 60, CO_2 18, respiratory alkalosis
Troponin -ve
CBC: WBC 10x10⁹/L (N 55, L 30, M 8, E 5),
Hb 12.5, Plt 760x10⁹/L
Coag WNL, , Cr 0.8

Radiology:

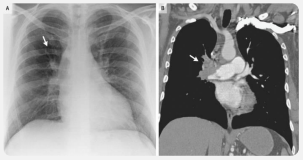

Echo. shows D shaped LV in diastole
CXR shows **Westermark sign** in the right lung.
CT chest demonstrates filling defects within the right pulmonary trunk.

Case 3

Essential thrombocythemia

Frequency +++ **Difficulty** ++ **Variety** +

Natural history

Incidence
1-2.5/100K
Median age 65-70
F > M

Pathogenesis
JAKV617F mutation
MPL mutation
CALR mutation

Clinical features
Asymptomatic
Thrombotic events
Bleeding events (Rare)
Slow progression
Less likely to progress to AML

Histology

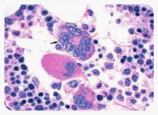

Megakaryocyte with staghorn nuclei

Assessment

Parameters
1. Age
2. Hx of thrombosis
3. CVS risk factors

Risk assessment
Low risk: -
Aspirin
Intermediate risk: 2
High risk: 1 or 3

Treatment

Medication
Aspirin
Hydroxyurea

Control metabolic

Prognosis

Life span
well controlled ET: similar to normal population

Virchow's triad

Arterial
- Inherited: Homocysteinemia?
- Acquired: Leukostatic syndrome in AML

Venous
- Inherited: Protein C, Protein S, Antithrombin deficiency, Factor V Leiden, Prothrombin G20210
- Acquired: Nephrotic syndrome

Both
- Malignancy, APS, Drugs (Estrogen, Thalidomide), DIC, TTP, PNH, HIT, MPNs, splenectomy, hyperviscosity syndrome

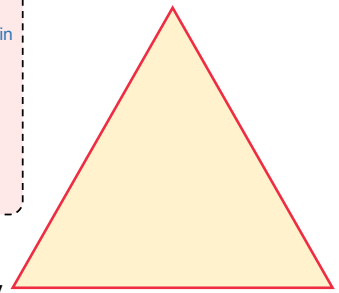

Endothelial injury

Arterial
- Atherosclerosis

Venous
- Catheter
- Local injury (Trauma, Surgery, Inflammation)

Venous stasis

Arterial
- Atrial fibrillation
- Aneurysm

Venous
- Immobilization
- Cast
- Venous compression
- Chronic venous insufficiency

Pathogenesis of thrombosis and fibrosis in essential thrombocythemia

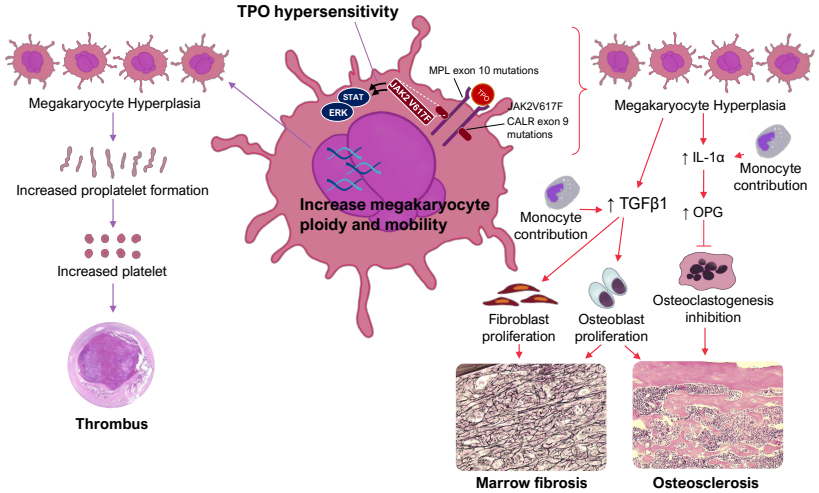

ET and thrombosis

- Thrombosis in ET is a result of **spontaneous activation and aggregation of hypersensitive platelets.**
- Risk factors predicting thrombotic events were;

Arterial thrombosis	Venous thrombosis
• Age >60 years • Previous thrombosis • Cardiovascular risk factors (smoking, hypertension, and diabetes) • WBC >11x109/L • Positivity of JAK2V617F	Male sex

- Pathophysiology supports the efficacy of antiplatelet and cytoreductive therapies in preventing and treating thrombosis and microvascular circulation disturbances.

ET and bleeding

- Prognostic factors in terms of bleeding complication include **platelet counts >1,000 ×10^9/L, WBC >11×10^9/L and splenomegaly**
- **Acquired von Willebrand syndrome (AVWS)** is a rare bleeding condition that is characterized by defects of von Willebrand factor (VWF) that are secondary to autoimmune, lymphoma, myeloproliferative neoplasms, or cardiovascular diseases.
- VWF abnormalities in these disorders can result from;
  - Antibody-mediated clearance or functional interference, or
  - Adsorption to surfaces of transformed cells or platelets, or
  - Increased shear stress and subsequent proteolysis.
- Therapeutic options of AVWS in ET include;
  - Cytoreductive therapy, removal apheresis (if symptomatic)
  - Additional treatments: withdraw aspirin (if applicable), desmopressin, antifibrinolytics, VWF-containing concentrate

WHO 2016

Philadelphia chromosome negative myeloproliferative neoplasm (Ph- MPN)

Polycythemia vera (PV)

Criteria for diagnosis of PV
Major:
1. Hb >16.5 g/dL (M), >16 g/dL (F) or Hct >49% (M), >48% (F) / RCM↑
2. BM biopsy: panmyelosis
3. JAK2 +ve

Minor: EPO level↓

Essential thrombocythemia (ET)

Criteria for diagnosis of ET
1. Platelet >450x10⁹/L
2. BM biopsy: hyperlobulated megakaryocyte↑, MF ≤1
3. Not meeting criteria of others
4. JAK2, CALR or MPL +ve

Primary myelofibrosis (PMF)

Criteria for diagnosis of overt PMF
Major:
1. BM biopsy: atypia megakaryocyte↑, MF 2-3
2. Not meeting criteria of others
3. JAK2, CALR or MPL +ve

Minor: LEB, LDH↑, Anemia, WBC >11x10⁹/L, Splenomegaly

Risk assessment

Low risk
- Age <60 and
- No history of thrombosis

- PV: Phlebotomy + low dose ASA
- ET: low dose ASA

(*JAK2-ve low risk ET: Observation)

Intermediate risk
- Age <60 and
- No history of thrombosis and
- One of CVS risk factors (DM, HT, DLP, Smoking)

- PV: Phlebotomy + low dose ASA
- ET: ASA

High risk
- Age >60 or
- Previous history of thrombosis or
- Platelet >1500x10⁹/L (ET)

- PV: Phlebotomy + low dose ASA + HU
- ET: ASA + HU

Risk assessment (DIPSS)
(Age, constitutional symptoms Hb, WBC, circulating blasts)

Low (0) / int-1 (1-2) risk → Symptom-directed treatment

Int-2 (3-4) / high (>5) risk → JAK inhibitor (Ruxolitinib) / AlloSCT

LEB = Leukoerythroblastosis
CCA = Clonal cytogenetic abnormalities

Suspected DVT: diagnosis and initial management

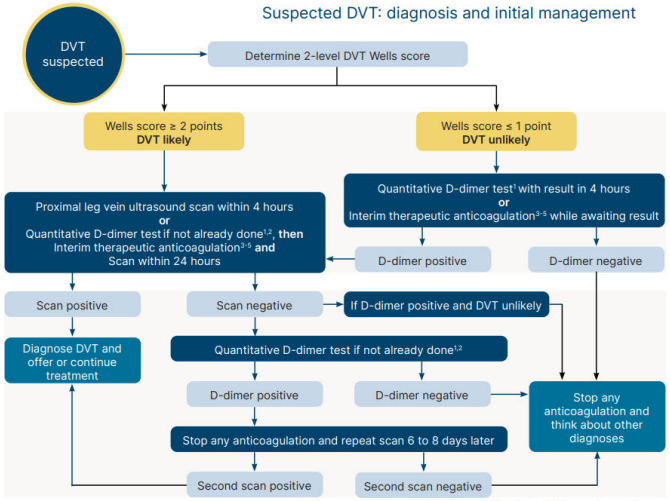

2-level DVT Wells score

Clinical feature	Points
Active cancer (treatment ongoing, within 6 months, or palliative)	1
Paralysis, paresis or recent plaster immobilisation of lower extremities	1
Recently bedridden for 3 days or more, or major surgery within 12 weeks requiring general or regional anaesthesia	1
Localised tenderness along the distribution of the deep venous system	1
Entire leg swollen	1
Calf swelling at least 3 cm larger than asymptomatic side	1
Pitting oedema confined to the symptomatic leg	1
Collateral superficial veins (non-varicose)	1
Previously documented DVT	1
An alternative diagnosis is at least as likely as DVT	-2
DVT likely: 2 points or more DVT unlikely: 1 point or less	

Adapted with permission from Wells et al. (2003)

NICE National Institute for Health and Care Excellence

[1]Laboratory or point-of-care test. Consider age-adjusted threshold for people over 50
[2]Note that only one D-dimer test is needed during diagnosis
[3]Measure baseline blood count, renal and hepatic function, PT and APTT but start anticoagulation before results available and review within 24 hours
[4]If possible, choose an anticoagulant that can be continued if DVT confirmed
[5]Direct-acting anticoagulants and some LMWHs are off label for use in suspected DVT. Follow GMC guidance on prescribing unlicensed medicines

Suspected PE: diagnosis and initial management

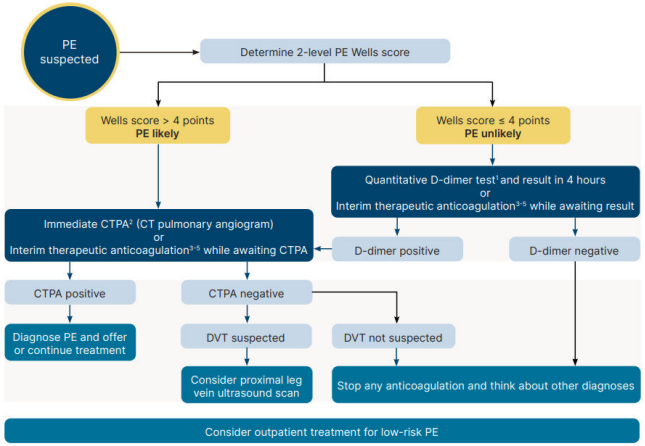

2-level PE Wells score

Clinical feature	Points
Clinical signs and symptoms of DVT (minimum of leg swelling and pain with palpation of the deep veins)	3
An alternative diagnosis is less likely than PE	3
Heart rate more than 100 beats per minute	1.5
Immobilisation for more than 3 days or surgery in previous 4 weeks	1.5
Previous DVT/PE	1.5
Haemoptysis	1
Malignancy (on treatment, treated in the last 6 months, or palliative)	1
PE likely: More than 4 points PE unlikely: 4 points or less	

Adapted with permission from Wells et al. (2000)

[1]Laboratory or point-of-care test. Consider age-adjusted threshold for people over 50
[2]CT pulmonary angiogram. Assess suitability of V/Q SPECT or V/Q planar scan for allergy, severe renal impairment (CrCl <30 ml/min estimated using the Cockcroft and Gault formula; see the BNF) or high irradiation risk
[3]Measure baseline blood count, renal and hepatic function, PT and APTT but start anticoagulation before results are available and review within 24 hours
[4]If possible, choose an anticoagulant that can be continued if PE is confirmed
[5]Direct-acting anticoagulants and some LMWHs are off label for use in suspected PE. Follow GMC guidance on prescribing unlicensed medicines

This is a summary of the recommendations on diagnosis and management from NICE's guideline on venous thromboembolic diseases. See the original guidance at www.nice.org.uk/guidance/NG158

DVT or PE: anticoagulation

PE with haemodynamic instability
Offer continuous UFH infusion and consider thrombolytic therapy

Body weight
If body weight <50 kg or >120 kg consider anticoagulant with monitoring of therapeutic levels.
Note cautions and requirements for dose adjustments and monitoring in SPCs. Follow local protocols, or specialist or MDT advice

INR monitoring
Do not routinely offer self-management or self-monitoring of INR

Prescribing in renal impairment and active cancer
Some LMWHs are off label in renal impairment, and most anticoagulants are off label in active cancer.
Follow GMC guidance on prescribing unlicensed medicines

Treatment failure
If anticoagulation treatment fails:
- check adherence
- address other sources of hypercoagulability
- increase the dose or change to an anticoagulant with a different mode of action

- Measure baseline full blood count, renal and hepatic function, PT and APTT but start anticoagulation before results available. Review and if necessary act on results within 24 hours
- Offer anticoagulation for at least 3 months. Take into account contraindications, comorbidities and the person's preferences
- After 3 months (3 to 6 months for active cancer) assess and discuss the benefits and risks of continuing, stopping or changing the anticoagulant with the person. See long-term anticoagulation for secondary prevention in the guideline

No renal impairment, active cancer, antiphospholipid syndrome or haemodynamic instability	**Renal impairment** (CrCl estimated using the Cockcroft and Gault formula; see the BNF)	**Active cancer** (receiving antimitotic treatment, diagnosed in past 6 months, recurrent, metastatic or inoperable)	**Antiphospholipid syndrome** (triple positive, established diagnosis)
Offer apixaban or rivaroxaban If neither suitable, offer one of: • LMWH for at least 5 days followed by dabigatran or edoxaban • LMWH and a VKA for at least 5 days, or until INR at least 2.0 on 2 consecutive readings, then a VKA alone	CrCl 15 to 50 ml/min, offer one of: • apixaban • rivaroxaban • LMWH for at least 5 days then – edoxaban **or** – dabigatran if CrCl ≥ 30 ml/min • LMWH or UFH and a VKA for at least 5 days, or until INR at least 2.0 on 2 consecutive readings, then a VKA alone CrCl < 15 ml/min, offer one of: • LMWH • UFH • LMWH or UFH and a VKA for at least 5 days, or until INR at least 2.0 on 2 consecutive readings, then a VKA alone Note cautions and requirements for dose adjustments and monitoring in SPCs. Follow local protocols, or specialist or MDT advice	Consider a DOAC If a DOAC is not suitable, consider one of: • LMWH • LMWH and a VKA for at least 5 days or until INR at least 2.0 on 2 consecutive readings, then a VKA alone Offer anticoagulation for 3 to 6 months Take into account tumour site, drug interactions including cancer drugs, and bleeding risk	Offer LMWH and a VKA for at least 5 days or until INR at least 2.0 on 2 consecutive readings, then a VKA alone

© NICE 2022. All rights reserved. Subject to Notice of rights.

Take home message

- ✓ Overview on long case examination
- ✓ How to approach the patient with hematologic condition
- ✓ Practices for long case scenario

Case 1:	50 y/o lawyer with chronic anemia	**MM stage 3 (transplant candidate)**
Case 2:	26 y/o teacher with mediastinal mass	**Hodgkin lymphoma (limited stage)**
Case 3:	65 y/o farmer with sudden hemiparesis	**ET (high risk) with acute PE**

Thank you for your attention

Nong Dang
& Kled Lek - Kled Noi
Blood cell characters

Sithakom Phusanti, MD.
Deputy director, Chakri Naruebodindra medical institute
Clinical instructor, Ramathibodi medical school
Hematologist, Ramadhibodi Chakri Naruebodindra hospital

Find us on facebook

น้องแดงและผองเพื่อน
facebook.com/nongdangandfriends